

High-grade glioma: ESMO Clinical Practice Guidelines for diagnosis, treatment and follow-up[†]

R. Stupp¹, M. Brada², M. J. van den Bent³, J.-C. Tonn⁴ & G. Pentheroudakis⁵ on behalf of the ESMO Guidelines Working Group*

¹Department of Oncology and Cancer Centre, University Hospital Zurich, Zurich, Switzerland; ²Department of Molecular and Clinical Cancer Medicine, University of Liverpool, Clatterbridge Cancer Centre, Wirral, UK; ³Department of Neuro-Oncology, Erasmus MC Cancer Center, Rotterdam, Netherlands; ⁴Department of Neurosurgery, Ludwig-Maximilians-University, Munich, Germany; ⁵Department of Medical Oncology, Medical School, University of Ioannina, Ioannina, Greece

Incidence and epidemiology

The yearly incidence of malignant glioma is ~3–5/100 000 with a slight predominance in males. Malignant glioma may develop at all ages, with the peak incidence being in the fifth and sixth decades of life [1–3]. Exposure to ionising irradiation has been associated with increased risk of development of glioma, while association with the use of cell phones could not be confirmed in epidemiological studies. Rare hereditary syndromes carry an increased risk for glioma: Cowden-, Turcot-, Lynch-, Li-Fraumeni syndrome and neurofibromatosis type 1.

Diagnosis and pathology

The commonly used World Health Organization (WHO) classification distinguishes tumours according to their presumed cell of origin (astrocytes or oligodendrocytes), and grades them from grade I–IV [4]. Grade I tumours occur mainly in childhood, and grade II (or low-grade) glioma are slow-growing tumours but will almost invariably transform over time to a more malignant phenotype. Grade III tumours (also commonly referred to as anaplastic glioma) comprise anaplastic astrocytoma, mixed anaplastic oligoastrocytoma and anaplastic oligodendroglioma, while glioblastoma (GBM) represents WHO grade IV. Tissue diagnosis is mandatory, and usually obtained by stereotactic biopsy or after tumour resection. GBM carries the worst prognosis, while pure oligodendroglioma has a protracted natural history and better outcome, and excellent response to therapy. Prognosis of mixed anaplastic oligoastrocytoma and anaplastic astrocytoma is intermediate between GBM and pure anaplastic oligodendroglioma. Concordance between local diagnosis and central neuropathology review can be as low as 50%, thus careful review of the histology by an expert neuropathology

team is recommended [5, 6]. Molecular markers are useful additional tools for diagnosis and treatment guidance (see below), and are of increasing importance in daily practice. Adequate tissue collection and preservation (e.g. sufficient material, fresh frozen tumour tissue) should be planned prospectively (see Table 1).

Molecular markers

Genetic loss on chromosomes 1p/19q (co-deletion or loss of heterozygosity [LOH] 1p/19q) is a consequence of a chromosomal translocation and describes a distinct tumour entity characterised by a prolonged natural history irrespective of treatment, and increased sensitivity both to radiotherapy (RT) and to chemotherapy [7]. LOH 1p/19q should be evaluated to support a diagnosis of oligodendroglioma.

Mutations of the *isocitrate dehydrogenase gene (IDH)* were recognised in 2008 as an early event in glioma genesis [8]. Mutations in the *IDH* gene 1 or 2 are hallmarks of low-grade glioma; when observed in high-grade glioma, it suggests that the tumour has developed from a lower grade precursor lesion (secondary GBM) [9, 10]. Less than 10% of individuals with adult GBM carry an *IDH* mutation, while ~60% of grade III tumours are *IDH*-mutated [8, 11]; *IDH*-mutated tumours are associated with a more favourable prognosis [12, 13]. Indeed, the survival of *IDH*-mutated GBM is more favourable than for non-mutated grade III astrocytoma, thus underscoring the strong prognostic value of this finding [10, 12]. The more frequent *IDH1* mutation accounts for ~90% of all *IDH* mutations and can be demonstrated by immunohistochemistry, while *IDH2* mutations and *IDH1* mutations at other sites can only be identified by sequencing. In lower grade tumours or suspected transformed glioma, *IDH* sequencing should be carried out if staining by immunohistochemistry with the anti-*IDH* antibody (which recognises R132H mutation) is negative.

Epigenetic silencing of the *methyl-guanine methyl transferase (MGMT)* gene promoter by gene promoter methylation suggests a partial inability of the tumour to repair the chemotherapy-induced DNA damage [14]. In retrospective analyses, *MGMT* methylation has been correlated with a response to or benefit

*Correspondence to: ESMO Guidelines Working Group, ESMO Head Office, Via L. Taddei 4, CH-6962 Viganello-Lugano, Switzerland.
E-mail: clinicalguidelines@esmo.org

[†]Approved by the ESMO Guidelines Working Group: December 2004, last update March 2014. This publication supersedes the previously published version—Ann Oncol 2010; 21(Suppl 5): v190–v193.

Table 1. Expected survival of glioma

Grade and cell type	Median survival
Grade II	
Astrocytoma	7–10 years
Oligodendroglioma ^a	>10–15 years
Grade III	
Anaplastic astrocytoma	3.5 years
Anaplastic oligodendroglioma ^a	>10 years
Grade IV	
Glioblastoma	15 months, 2-year survival 27%
MGMT	
Methylated	23 months, 2-year survival: 49%
Unmethylated	13 months, 2-year survival: 12%

^aWith LOH 1p/19q. MGMT, methyl-guanine methyl transferase

of alkylating agent chemotherapy [II, B] [15, 16]. MGMT determination by immunohistochemistry lacks standardisation, reproducibility and, most importantly, correlation with clinical outcome [III, C], while MGMT status determination by methylation-specific polymerase chain reaction (MSP) has been largely standardised and allows for reproducible results [17, 18]. A predictive value of a methylated MGMT status for response to or benefit from alkylating agent chemotherapy and thus improved outcome has been demonstrated repeatedly in GBM [19, 20]. However, in lower grade IDH-mutated tumours, MGMT methylation identifies a sub-population with a better prognosis irrespective of the applied treatment [18].

The determination of these markers is now part of routine practice; however, whether MGMT methylation status determination is carried out for an individual patient depends on the diagnostic and therapeutic context (Table 2). In the absence of clinical consequences and better alternative treatments, MGMT status assessment may not be necessary for every patient [V, D]; nevertheless, in elderly patients improved outcome with adapted treatment strategy [i.e. temozolomide (TMZ) chemotherapy for MGMT-methylated tumours, radiotherapy for unmethylated tumours] has been demonstrated in two randomised trials [II, A] [19, 20]. In current clinical trials, MGMT status is always required as a stratification factor. For a detailed discussion, the reader is referred to recent extensive reviews [18].

These markers are neither mutually exclusive nor entirely independent. MGMT promoter methylation is highly associated with LOH 1p/19q and IDH mutations [11]. MGMT methylation is predictive for benefit from alkylating agent chemotherapy in GBM, while it confers a largely prognostic value in anaplastic grade III tumours. A recent report from the Neuro-Oncology Working Group (NOA) of the German Cancer Society confirmed a predictive value of MGMT methylation for benefit from chemotherapy in patients with a wild-type IDH, independent of tumour grade [21].

staging and risk assessment

Although glioma are invasive tumours with a strong propensity of glioma cells to migrate, tumour dissemination remains

limited to the central nervous system and distant metastases are virtually non-existent; thus, staging focuses on imaging of the brain, ideally by magnetic resonance imaging (MRI). The spine and cerebrospinal fluid (CSF) are not routinely assessed in the absence of clinical symptoms. Ideally, the extent of tumour resection and determination of residual disease should be assessed after surgery; however, this assessment must be carried out within 24–48 h in order to distinguish post-surgical contrast enhancement from residual tumour. Lower tumour grade, radical tumour resection, younger age (<50 years), good performance status and an intact neurological function are favourable prognostic factors. Determination of molecular markers (discussed above) will identify patients with a more favourable prognosis or better chance of response to alkylating agent chemotherapy.

disease management and treatment plan

general management

Patients should be evaluated and the treatment plan determined by a specialised multidisciplinary team including neurosurgeons, medical and radiation oncologists, but also an expert neuropathologist and neuroradiologist. Special consideration should be given to performance status and neurological function. Corticosteroids (usually dexamethasone 8–16 mg/day, but lower doses may be just as effective) allow for rapid reduction of tumour-associated oedema and improve clinical symptoms. Patients' glucose levels need to be monitored. Steroids are not necessary in patients without increased intracranial pressure or in the absence of oedema-associated neurological deficits. There is no need for prolonged steroid therapy after tumour resection or for prophylaxis during radiotherapy in asymptomatic patients. Rapid tapering and discontinuation of corticosteroids is recommended in order to avoid toxicity associated with prolonged exposure to steroids, e.g. myopathy and weakness, lymphopenia and risk of infection, osteoporosis and Cushing syndrome.

Anti-epileptic therapy is indicated in patients presenting with seizures; however, prophylactic use of anticonvulsants outside the perioperative phase is not indicated [III, C]. After tumour resection, the indication for anti-seizure therapy should be revisited only if seizures occur [22, 23]. First generation anti-epileptic drugs (phenytoin, carbamazepine, phenobarbital and their derivatives) are strong inducers of the hepatic metabolism, and may interfere with medications including many commonly used chemotherapy agents (but not with TMZ). Agents such as lamotrigine, levetiracetam, pregabalin or valproic acid are preferred.

Glioma patients are at increased risk of thromboembolic events due to a tumour-induced hyper-coagulable state, but also as a consequence of neurological deficits, immobilisation and steroid use [24]. Prophylactic anticoagulation is not recommended; however, a low threshold for excluding deep vein thrombosis and pulmonary emboli is indicated when suspicious symptoms occur. The presence of a brain tumour is not a contraindication for the use of standard anticoagulants in patients with proven thrombosis.

newly diagnosed patients

Surgery is commonly the initial therapeutic approach for tumour debulking and obtaining tissue for diagnosis. Tumour

Downloaded from <http://annonc.oxfordjournals.org/> by guest on January 2, 2017

Table 2. Clinically relevant molecular markers (adapted from [70] with permission from Elsevier)

	<i>IDH1/2</i> mutation	1p/19q co-deletion	<i>MGMT</i> promoter methylation
Biological consequence	Increased levels of 2-hydroxyglutarate, link to G-CIMP phenotype	Unclear, candidate genes <i>CIC</i> and <i>FUBP1</i> under investigation	Reduced DNA repair, association with G-CIMP phenotype in <i>IDH1/2</i> -mutant tumours
Methods of assessment	Immunohistochemistry for <i>IDH1</i> -R132H; if negative, gene sequencing	FISH, micro-satellite analysis for loss of heterozygosity	MSP, MS or bisulphite (pyro)sequencing
Frequency			
WHO grade II			
Diffuse astrocytoma	70%–80%	15%	40%–50%
Oligodendroglioma/ oligoastrocytoma	70%–80%	30%–60%	60%–80%
WHO grade III			
Anaplastic astrocytoma	50%–70%	15%	50%
Anaplastic Oligodendroglioma/ oligoastrocytoma	50%–80%	50%–80%	70%
WHO grade IV			
Glioblastoma	5%–10%	<5%	35%
Diagnostic role	DD glioma versus gliosis Typical for transformed low-grade glioma	Pathognomonic for oligodendroglioma	None
Prognostic role	Protracted natural history in <i>IDH</i> -mutated tumours	Protracted natural history in 1p/19q codeleted tumours	Prognostic for anaplastic glioma patients (possibly with <i>IDH</i> mutations) treated with radiotherapy or alkylating drugs
Predictive role	Absence of mutation suggests predictive role for <i>MGMT</i> promoter methylation	Prolongation of survival with early chemotherapy in 1p/19-co-deleted oligodendrogliomas	Predictive in GBM for benefit from alkylating chemotherapy Elderly GBM: <i>MGMT</i> -methylated → TMZ <i>MGMT</i> -unmethylated → RT

WHO, World Health Organization; G-CIMP, glioma CpG island methylator phenotype; *IDH*, isocitrate dehydrogenase; DD, differential diagnosis; *MGMT*, methyl-guanine methyl transferase; *CIC*, capicua transcriptional repressor; *FUBP1*, far upstream element (FUSE) binding protein 1; FISH, fluorescence in situ hybridisation; DNA, deoxyribonucleic acid; MSP, methylation-specific PCR; MS, methylation-specific; GBM, glioblastoma; TMZ, temozolomide; RT, radiotherapy.

resection is of prognostic value; it may be beneficial to attempt maximal tumour resection provided that neurological function is not compromised by the extent of resection [II, C] [25]. An increase in the complete resection rate and improvement in progression-free survival (PFS) have been shown when surgery is carried out under blue light with the use of fluorescent marking of the tumour by 5-amino-laevulinic acid (5-ALA) [26]. When microsurgical resection is not safely feasible (e.g. due to location of the tumour or impaired clinical condition of the patient), a biopsy should be carried out. In experienced hands, the diagnostic yield is >95% [18]. A sufficient amount of tissue should be obtained for molecular analyses, and open biopsies may yield more tissue to allow this compared with stereotactic biopsies. On freshly frozen specimens, molecular genetic analyses (LOH 1p/19q, *MGMT* promoter methylation) can be carried out even with small amounts of tissue, and this should be planned beforehand [27].

Implantation of chemotherapy-impregnated wafers (carmustine polymers) into the resection cavity before radiotherapy has been shown to marginally improve median survival compared with radiotherapy alone [II, B] [28]; however, no prospective data are available when compared with current standard TMZ/RT (see below) [29]. An increase in wound healing and infectious complications has been reported. The combination of carmustine wafers and TMZ/RT has not been assessed in prospective trials, a retrospective comparison failed to demonstrate additive efficacy [IV, D] [30].

Fractionated localised radiotherapy (60 Gy, 30–33 fractions of 1.8–2 Gy, or equivalent doses/fractionations) is part of the standard treatment after resection or biopsy [I, A] [31]. Escalating doses beyond 60 Gy have not been shown to be of value. In elderly patients or patients with a low performance status, shorter hypo-fractionated regimens (e.g. 40 Gy in 15 fractions) are commonly proposed [II, B] [32]. Radiotherapy (28 × 1.8 Gy, 50 Gy) in patients >70 years of age was superior to best supportive care alone in a randomised phase III trial [II, B] [33]. Exclusive TMZ chemotherapy has shown an improved outcome compared with radiotherapy alone in elderly patients with a methylated *MGMT* gene promoter in two randomised trials [II, A] [19, 20] (see Figure 1).

glioblastoma (WHO grade IV)

Concomitant and adjuvant TMZ chemotherapy in addition to radiotherapy (TMZ/RT → TMZ) significantly improved median, 2- and 5-year survival in a large randomised trial, and is the current standard of care for patients with GBM up to age 70 [34, 35] [I, A], or fit elderly patients older than 70 years [II, B] [36]. TMZ is administered daily (7 days a week) during radiotherapy and for 5 days every 4 weeks for six cycles as maintenance (adjuvant) treatment after the end of radiation. *MGMT* gene promoter methylation has been demonstrated as the strongest prognostic marker for outcome, and the added benefit of TMZ

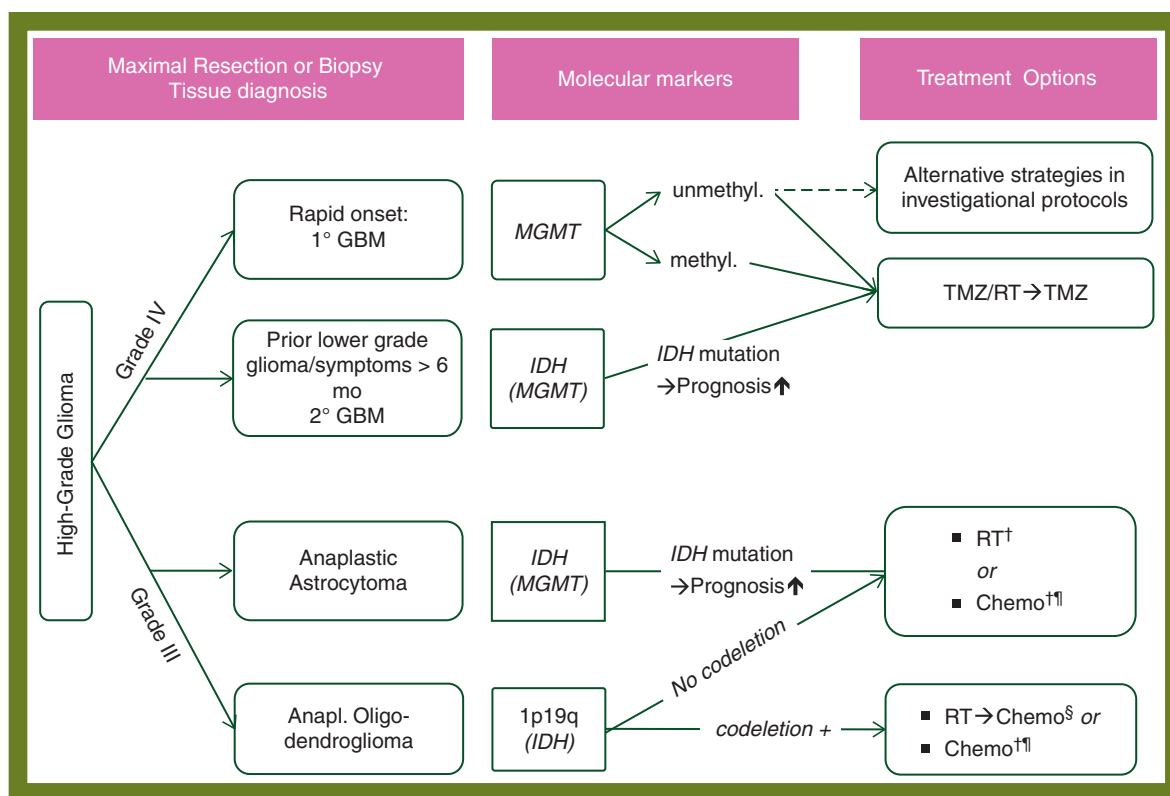


Figure 1. Treatment algorithm for high-grade glioma. GBM, glioblastoma; 1°, primary; 2°, secondary; *MGMT*, methyl-guanin methyltransferase gene promoter methylation status; IDH, isocitrate dehydrogenase gene mutation; LOH 1p/19q, loss of heterozygosity of chromosomes 1 and 19; RT, radiotherapy; Chemo, chemotherapy with either PCV or temozolomide; PCV, procarbazine, lomustine [CCNU], vincristine; TMZ, temozolomide. †, RT or chemotherapy first, and at progression chemo or RT, respectively (according to NOA-04 study). ‡, no randomised data for oligodendroglioma, only class III + V evidence. §, subgroup analysis and long-term follow-up of RTOG and EORTC randomised studies demonstrated prolonged survival for patients treated with RT → PCV.

chemotherapy appears largely restricted to this subgroup [16]. Feasibility of upfront testing and stratification by *MGMT* status has been demonstrated in large prospective trials, and alternative strategies for patients with unmethylated *MGMT* are proposed to patients as part of ongoing clinical trials. In the absence of effective better alternatives, TMZ/RT → TMZ remains the standard of care for the majority of GBM patients [II, B].

Owing to the overall inferior prognosis of elderly patients, shorter, simpler and less intensive treatment strategies have been investigated in frail or elderly patients approximately >65 years of age. Although hypo-fractionated RT (10×3.4 or 15×2.66 Gy) has been shown equivalent to standard fractionated irradiation with 30 fractions (60 Gy) in one trial [II, A] [32], the 6-week regimen was inferior compared with hypo-fractionated RT in patients >70 years in a subsequent larger randomised trial [19, 32], supporting the practice of administering RT as a short hypo-fractionated course in elderly patients. Primary chemotherapy versus radiotherapy has been compared in two randomised phase III trials reported in 2012 [19, 20]. Consistently, both trials have demonstrated a poor median overall survival (OS) of 7–9 months. *MGMT* promoter methylation was strongly predictive for a benefit from TMZ chemotherapy, suggesting that patients with a methylated *MGMT* are better treated with chemotherapy, while patients with an unmethylated *MGMT* should be managed with radiotherapy alone [II, A] [19, 20]. In the absence of information on the *MGMT* status, the appropriate treatment is hypo-fractionated radiotherapy [II, A] [33]. A randomised, controlled trial (clinicaltrials.gov: NCT#00482677) investigating hypo-fractionated RT ± concomitant and maintenance TMZ completed recruitment in 2013; first results are expected in late 2014.

Recent large phase III trials of novel treatment approaches failed to improve survival of patients with newly diagnosed GBM. Dose intensification of the adjuvant or maintenance TMZ therapy [36], the addition of cilengitide [37] or the addition of bevacizumab [38, 39] did not translate into prolongation of OS. The clinical value of the observed prolonged PFS with bevacizumab remains controversial. The reported median OS from surgery in these clinical trials is ~16–18 months for both the control and experimental arms, and no substantial improvement over the results of the initial European Organisation for Research and Treatment of Cancer (EORTC)/National Cancer Institute of Canada TMZ trial [median 15 months, 95% confidence interval (CI) 13–17 months] was demonstrated.

anaplastic astrocytoma, oligoastrocytoma and oligodendroglioma (WHO grade III)

Anaplastic astrocytoma and oligoastrocytoma have a better prognosis compared with glioblastoma. Standard therapy consists of adjuvant radiotherapy up to 60 Gy after surgery. The value of concomitant and/or maintenance chemotherapy with TMZ has not been tested prospectively [V, D]. Long-term follow-up (10 years) of randomised clinical trials demonstrated prolonged survival with (neo)adjuvant PCV chemotherapy (procarbazine, lomustine [CCNU], vincristine) in newly diagnosed anaplastic oligoastrocytoma and oligodendroglioma [40, 41], but benefit was mainly present in prognostically favourable molecular subgroups of patients (in particular co-deletion of 1p/19q) [II, B]. In a more recent randomised trial with follow-up data currently available up

to 4.5 years, time to failure of both chemotherapy and radiation was similar whether patients were treated initially with chemotherapy (and received RT at first progression) or were treated with initial RT (and received chemotherapy at progression) [I, A] [42]. An updated report is awaited. No difference of efficacy was apparent between PCV or TMZ chemotherapy [II, B].

diffuse glioma (WHO grade II)

Diffuse gliomas are low-grade tumours and comprise the histological subtypes of astrocytoma, oligoastrocytoma and oligodendroglioma. Although they have a protracted natural history of years or occasionally decades, and may not need immediate therapy, these tumours invariably recur and often transform into a higher histological grade.

The diagnosis is often made after an initial seizure is observed as a presenting symptom, or when imaging of the brain is carried out to investigate neurological deficits, changes in mood or personality. At that time, the tumour may already have grown to a substantial size without causing evident neurological dysfunction, due to its slow growth over many years.

Radical surgery both for diagnostic and therapeutic purposes is the backbone of low-grade glioma management. It is assumed that, by resection of all visible tumour tissue, the risk of subsequent malignant transformation is substantially reduced [III, B].

In an exemplary randomised trial, investigators from the EORTC have demonstrated that an 'expectative' or cautious approach—delaying additional radiotherapy until symptoms prevail and the tumour has grown to >5–6 cm—will substantially delay or eliminate the need for irradiation in a significant number of patients [I, A] [43]. Adjuvant radiotherapy for a total dose of 50.4 Gy (28×1.8 Gy) is the accepted standard of care [I, A]. Two randomised trials investigated lower (45–50.4 Gy) versus higher dose (59.4–64.8 Gy) of irradiation; the lower dose was equivalent to the higher dose with less toxicity [44, 45]. Based on these trials, a number of negative prognostic factors were identified: tumour size >5–6 cm, tumours crossing the mid-line, absence of oligodendroglial histology, age >40 years and neurological deficits before surgery [46]. Three or more of these risk factors are considered an indication for adjuvant radiotherapy. A contemporary randomised trial compared adjuvant single-agent TMZ chemotherapy (without radiation) with standard radiotherapy. Preliminary results were presented at the American Society of Clinical Oncology meeting in 2013, and demonstrated that PFS analysis favours radiotherapy; however, follow-up is too early for firm conclusions and survival results are not yet mature [47]. Molecular characterisation of tumours may allow identification of subgroups of patients benefiting from one of the other treatment modalities, with 1p/19q co-deleted tumours having a similar PFS after TMZ chemotherapy compared with radiotherapy. The Radiation Therapy Oncology Group (RTOG) has conducted a randomised trial in a similar population exploring the efficacy of adjuvant PCV chemotherapy after radiotherapy. At the time of first presentation, the follow-up data were immature; thus, definitive conclusions are not yet possible [48].

recurrent disease

Some benefit of chemotherapy has been shown for patients with an adequate performance status who have not received prior

adjuvant cytotoxic therapy. Relapsing low-grade astrocytoma, anaplastic astrocytomas and oligodendrogliomas are more likely than GBM to respond to TMZ chemotherapy [III, B] [49, 50]. For patients progressing after prior chemotherapy, there is no established chemotherapy regimen available and patients are best treated within investigational clinical protocols. Chemotherapy with PCV or single-agent nitrosourea therapy may achieve similar tumour control rates compared with TMZ [51–53]. Randomised trials in recurrent glioblastoma have failed to demonstrate measurable anti-tumour efficacy of epidermal growth factor receptor (EGFR) inhibition by erlotinib or platelet-derived growth factor receptor inhibition by imatinib in an unselected patient population [II, C] [54, 55]. High response rates and a steroid-sparing effect have been observed with the administration of bevacizumab (\pm irinotecan); however, the effect is frequently short-lived and may be due exclusively to changes in vascular permeability; the effect on life expectancy remains unknown [III, C] [56, 57]. Randomised trials evaluating the pan-vascular endothelial growth factor receptor inhibitor cediranib or protein kinase C inhibitor enzastaurin failed to demonstrate improved outcome, and provide contemporary data on the limited but confirmed single-agent efficacy of lomustine (CCNU) [52, 53]. Applying alternating electric fields—tumour-treating fields (TTFs)—using a battery-powered device connected to electrodes placed on the patient's scalp—was compared with physicians' choice of chemotherapy in a randomised trial in recurrent disease [58]. TTF failed to prolong survival compared with second-line chemotherapy [I, A].

There may be an indication for a re-operation [IV, C], in particular in patients where the recurrent tumour exerts an acute mass effect. However, there are no prospective data available on the impact of repeat surgery on OS. Retrospective analyses on selected patients did not identify surgery for recurrent disease as a significant prognostic factor for prolonged survival [59, 60]. Repeat surgery and implantation of carmustine-impregnated polymers may lead to marginal prolongation of survival compared with placebo, as demonstrated in a randomised trial conducted in the early 1990s [II, B] [61].

Re-irradiation is being considered increasingly for recurrent small tumours [IV, C], although there is considerable doubt about its benefit and the literature lacks prospective and comparative trials [62, 63]. The few limited size case series do not allow for any conclusion.

response evaluation

MRI is the preferred imaging method. Increased contrast enhancement and presumed tumour progression on imaging 4–12 weeks after the end of radiotherapy may be due to a reactive process following radiotherapy (pseudo-progression) [64, 65]. Early presumed progression after the end of radiotherapy should raise the possibility of pseudo-progression, and chemotherapy should be continued as planned with repeat imaging after 6–8 weeks. An incidence of $>60\%$ pseudo-progression has been reported among patients with early radiological progression after radiochemotherapy [66].

Response to chemotherapy is currently evaluated according to the 2D Response Assessment in Neuro-Oncology (RANO) criteria, in which in addition to contrast enhancement, tumour extension on T_2 - and fluid-attenuated inversion recovery

(FLAIR)-weighted MRI are evaluated [67]. Furthermore, an assessment of neurological function and corticosteroid use is included. The recent introduction of anti-angiogenic and vascular modifying agents led to a reassessment of response criteria, in which, in addition to contrast enhancement, tumour extension on T_2 - and FLAIR-weighted MRI are to be evaluated [67]. In cases of doubtful differential diagnosis between tumour recurrence and treatment-induced unspecific changes (especially after multimodal therapy), magnetic resonance spectroscopy and positron-emission tomography investigation using an amino acid tracer (e.g. methionine, fluoro-ethyl-tyrosine) may be helpful [III, B] [68]. However, often both residual tumour and necrotic and inflammatory changes are present in the same lesion.

personalised medicine

Recent investigation of molecular markers, gene expression, whole genome sequencing and epigenetics has enabled identification of patient subgroups according to pathway activation, specific aberrations or pathognomonic molecular characteristics [69]. The clinical utility of *IDH* mutations, LOH 1p/19q and *MGMT* promoter methylation in prognostication and their predictive value and role in clinical decision-making have been discussed in the relevant subheadings above. *ATRX* mutations have been identified to be specific for astrocytic lineage. Other markers like EGFR overexpression and *EGFR variant III* (*EGFRviii*) mutation are characteristic for GBM that carry an inferior prognosis (reviewed in [70]). Targeting the EGFR with specific inhibitors and vaccination against EGFRviii are currently under clinical investigation [71]. Rare activating BRAF mutations can be identified in 3%–5% of GBM; whether the BRAF inhibitors are effective (alone or in combination) in this subgroup of tumours is subject of ongoing clinical research protocols. All planned investigational protocols are being designed for specific subgroups, selecting and enriching for specific molecular aberrations when targeting activated pathways.

follow-up and long-term implications

Follow-up consists of a clinical evaluation with particular attention to neurological function, seizures and corticosteroid use. Patients should be tapered off steroid use as early as possible. Venous thrombotic events occur frequently in patients with residual or recurrent tumours. Laboratory tests are not indicated unless the patient is receiving chemotherapy (blood counts), corticosteroids (glucose) or anti-epileptic drugs (blood count, liver function tests). MRI every 3–4 months is standard practice outside clinical trials, unless more frequent monitoring is clinically indicated.

note

A summary of recommendations is provided in Table 3. Levels of evidence and grades of recommendation have been applied using the system shown in Table 4. Statements without grading were considered justified standard clinical practice by the expert authors and the ESMO faculty.

Table 3. Conclusions and recommendations

Histological diagnosis is mandatory and should include sufficient tissue for molecular tumour characterisation
Methyl-guanine methyl transferase (<i>MGMT</i>) promoter methylation, isocitrate dehydrogenase gene (<i>IDH</i>) mutations and co-deletions of 1p/19q are commonly determined depending on the histological and clinical context
Surgery to the extent feasible is the first therapeutic intervention for all malignant glioma
For glioblastoma, combined modality therapy with temozolomide (TMZ) and radiotherapy remains the standard of care
In elderly patients and a methylated <i>MGMT</i> promoter, exclusive TMZ chemotherapy may be considered, while (hypo-fractionated) radiotherapy is the treatment of choice for patients with an unmethylated gene promoter
Anaplastic oligodendroglioma should receive radiotherapy and adjuvant chemotherapy, while no benefit has been demonstrated for adjuvant PCV chemotherapy (procarbazine, lomustine [CCNU], vincristine) in anaplastic astrocytoma
In anaplastic glioma, treatment with adjuvant chemotherapy alone and irradiation only at the time of tumour progression is equivalent to the standard sequence of initial radiotherapy and salvage chemotherapy at the time of progression

Table 4. Levels of evidence and grades of recommendation (adapted from the Infectious Diseases Society of America–United States Public Health Service Grading System^a)

Levels of evidence	
I	Evidence from at least one large randomised, controlled trial of good methodological quality (low potential for bias) or meta-analyses of well-conducted randomised trials without heterogeneity
II	Small randomised trials or large randomised trials with a suspicion of bias (lower methodological quality) or meta-analyses of such trials or of trials with demonstrated heterogeneity
III	Prospective cohort studies
IV	Retrospective cohort studies or case–control studies
V	Studies without control group, case reports, experts opinions
Grades of recommendation	
A	Strong evidence for efficacy with a substantial clinical benefit, strongly recommended
B	Strong or moderate evidence for efficacy but with a limited clinical benefit, generally recommended
C	Insufficient evidence for efficacy or benefit does not outweigh the risk or the disadvantages (adverse events, costs, ...), optional
D	Moderate evidence against efficacy or for adverse outcome, generally not recommended
E	Strong evidence against efficacy or for adverse outcome, never recommended

^aBy permission of the Infectious Diseases Society of America [72].

conflict of interest

RS has reported that he is the president of EORTC, and has acted the principal investigator in pivotal studies investigating temozolomide, cilengitide or NovoTTF. He has received honoraria for advisory board participation from Roche/Genentech, and MSD/Merck & Co. He also received remuneration for participation in Advisory Boards organised by Roche, Amgen, AstraZeneca, Celgene and Sanofi. GP has reported research sponsored by Amgen, Teva, Roche, Boehringer Ingelheim and Sanofi. JCT has reported speaker's honoraria and Advisory boards of Roche, MerckSereno and Medac. MV has reported that he is conducting research sponsored by Roche and by AbbVie. He is a member of the speaker's bureau of MSD, and he has also received honoraria from Roche, AMGEN, Actelion, Merck AG, Celldex and AbbVie. MB has reported no potential conflicts of interest.

references

1. Preusser M, de Ribaupierre S, Wöhrer A et al. Current concepts and management of glioblastoma. *Ann Neurol* 2011; 70: 9–21.
2. Wen PY, Kesari S. Malignant gliomas in adults. *N Engl J Med* 2008; 359: 492–507.
3. Ferlay J, Parkin DM, Steliarova-Foucher E. Estimates of cancer incidence and mortality in Europe in 2008. *Eur J Cancer* 2010; 46: 765–781.
4. Louis DN, Ohgaki H, Wiestler O et al. WHO Classification of Tumours of the Central Nervous System, 4th Edn. Lyon: International Agency for Research on Cancer 2007.
5. Kros JM, Gorlia T, Kouwenhoven MC et al. Panel review of anaplastic oligodendroglioma from European Organization For Research and Treatment of Cancer Trial 26951: assessment of consensus in diagnosis, influence of 1p/19q loss, and correlations with outcome. *J Neuropathol Exp Neurol* 2007; 66: 545–551.
6. Hegi ME, Janzer RC, Lambiv WL et al. Presence of an oligodendroglioma-like component in newly diagnosed glioblastoma identifies a pathogenetically heterogeneous subgroup and lacks prognostic value: central pathology review of the EORTC_26981/NCIC_CE.3 trial. *Acta Neuropathol* 2012; 123: 841–852.
7. Jenkins RB, Blair H, Ballman KV et al. A t(1;19)(q10;p10) mediates the combined deletions of 1p and 19q and predicts a better prognosis of patients with oligodendroglioma. *Cancer Res* 2006; 66: 9852–9861.
8. Yan H, Parsons DW, Jin G et al. IDH1 and IDH2 mutations in gliomas. *N Engl J Med* 2009; 360: 765–773.
9. Sturm D, Witt H, Hovestadt V et al. Hotspot mutations in H3F3A and IDH1 define distinct epigenetic and biological subgroups of glioblastoma. *Cancer Cell* 2012; 22: 425–437.
10. Hartmann C, Hentschel B, Simon M et al. Long-term survival in primary glioblastoma with versus without isocitrate dehydrogenase mutations. *Clin Cancer Res* 2013; 19: 5146–5157.
11. Sanson M, Marie Y, Paris S et al. Isocitrate dehydrogenase 1 codon 132 mutation is an important prognostic biomarker in gliomas. *J Clin Oncol* 2009; 27: 4150–4154.
12. Hartmann C, Hentschel B, Wick W et al. Patients with IDH1 wild type anaplastic astrocytomas exhibit worse prognosis than IDH1-mutated glioblastomas, and IDH1 mutation status accounts for the unfavorable prognostic effect of higher age: implications for classification of gliomas. *Acta Neuropathol* 2010; 120: 707–718.
13. Schittenhelm J, Mittelbronn M, Meyermann R et al. Confirmation of R132H mutation of isocitrate dehydrogenase 1 as an independent prognostic factor in anaplastic astrocytoma. *Acta Neuropathol* 2011; 122: 651–652.
14. Hegi ME, Liu L, Herman JG et al. Correlation of O6-methylguanine methyltransferase (*MGMT*) promoter methylation with clinical outcomes in glioblastoma and clinical strategies to modulate *MGMT* activity. *J Clin Oncol* 2008; 26: 4189–4199.

15. Hegi ME, Diserens AC, Godard S et al. Clinical trial substantiates the predictive value of O-6-methylguanine-DNA methyltransferase promoter methylation in glioblastoma patients treated with temozolomide. *Clin Cancer Res* 2004; 10: 1871–1874.
16. Hegi ME, Diserens AC, Gorlia T et al. *MGMT* gene silencing and benefit from temozolomide in glioblastoma. *N Engl J Med* 2005; 352: 997–1003.
17. Preusser M, Charles Janzer R, Felsberg J et al. Anti-O6-methylguanine-methyltransferase (MGMT) immunohistochemistry in glioblastoma multiforme: observer variability and lack of association with patient survival impede its use as clinical biomarker. *Brain Pathol* 2008; 18: 520–532.
18. Weller M, Stupp R, Reifenberger G et al. *MGMT* promoter methylation in malignant gliomas: ready for personalized medicine? *Nat Rev Neurol* 2010; 6: 39–51.
19. Malmström A, Grönberg BH, Marosi C et al. Temozolomide versus standard 6-week radiotherapy versus hypofractionated radiotherapy in patients older than 60 years with glioblastoma: the Nordic randomised, phase 3 trial. *Lancet Oncol* 2012; 13: 916–926.
20. Wick W, Platten M, Meisner C et al. Temozolomide chemotherapy alone versus radiotherapy alone for malignant astrocytoma in the elderly: the NOA-08 randomised, phase 3 trial. *Lancet Oncol* 2012; 13: 707–715.
21. Wick W, Meisner C, Hentschel B et al. Prognostic or predictive value of *MGMT* promoter methylation in gliomas depends on IDH1 mutation. *Neurology* 2013; 81: 1515–1522.
22. Rossetti AO, Stupp R. Epilepsy in brain tumor patients. *Curr Opin Neurol* 2010; 23: 603–609.
23. Weller M, Stupp R, Wick W. Epilepsy meets cancer: when, why, and what to do about it? *Lancet Oncol* 2012; 13: e375–e382.
24. Perry JR. Thromboembolic disease in patients with high-grade glioma. *Neuro Oncol* 2012; 14(Suppl. 4): iv73–iv80.
25. Lacroix M, Abi-Said D, Fourney DR et al. A multivariate analysis of 416 patients with glioblastoma multiforme: prognosis, extent of resection, and survival. *J Neurosurg* 2001; 95: 190–198.
26. Stummer W, Pichlmeier U, Meinel T et al. Fluorescence-guided surgery with 5-aminolevulinic acid for resection of malignant glioma: a randomised controlled multicentre phase III trial. *Lancet Oncol* 2006; 7: 392–401.
27. Stupp R, Hegi ME, Gilbert MR, Chakravarti A. Chemoradiotherapy in malignant glioma: standard of care and future directions. *J Clin Oncol* 2007; 25: 4127–4136.
28. Westphal M, Hilt DC, Bortey E et al. A phase 3 trial of local chemotherapy with biodegradable carmustine (BCNU) wafers (Gliadel wafers) in patients with primary malignant glioma. *Neuro Oncol* 2003; 5: 79–88.
29. Gutenberg A, Lumenta CB, Braunsdorf WE et al. The combination of carmustine wafers and temozolomide for the treatment of malignant gliomas. A comprehensive review of the rationale and clinical experience. *J Neurooncol* 2013; 113: 163–174.
30. Noël G, Schott R, Froelich S et al. Retrospective comparison of chemoradiotherapy followed by adjuvant chemotherapy, with or without prior gliadel implantation (carmustine) after initial surgery in patients with newly diagnosed high-grade gliomas. *Int J Radiat Oncol Biol Phys* 2012; 82: 749–755.
31. Walker MD, Green SB, Byar DP et al. Randomized comparisons of radiotherapy and nitrosoureas for the treatment of malignant glioma after surgery. *N Engl J Med* 1980; 303: 1323–1329.
32. Roa W, Brasher PM, Bauman G et al. Abbreviated course of radiation therapy in older patients with glioblastoma multiforme: a prospective randomized clinical trial. *J Clin Oncol* 2004; 22: 1583–1588.
33. Keime-Guibert F, Chinot O, Taillandier L et al. Radiotherapy for glioblastoma in the elderly. *N Engl J Med* 2007; 356: 1527–1535.
34. Stupp R, Mason WP, van den Bent MJ et al. Radiotherapy plus concomitant and adjuvant temozolomide for glioblastoma. *N Engl J Med* 2005; 352: 987–996.
35. Stupp R, Hegi ME, Mason WP et al. Effects of radiotherapy with concomitant and adjuvant temozolomide versus radiotherapy alone on survival in glioblastoma in a randomised phase III study: 5-year analysis of the EORTC-NCIC trial. *Lancet Oncol* 2009; 10: 459–466.
36. Gilbert MR, Wang M, Aldape KD et al. Dose-dense temozolomide for newly diagnosed glioblastoma: a randomized phase III clinical trial. *J Clin Oncol* 2013; 31: 4085–4091.
37. Stupp R, Hegi ME, Gorlia T et al. Cilengitide combined with standard treatment for patients with newly diagnosed glioblastoma and methylated O6-methylguanine-DNA methyltransferase (*MGMT*) gene promoter: key results of the multicenter, randomized, open-label, controlled, phase III CENTRIC study. *ASCO Meeting Abstracts*. *J Clin Oncol* 2013; 31: LBA2009.
38. Gilbert MR, Dignam JJ, Armstrong TS et al. A randomized trial of bevacizumab for newly diagnosed glioblastoma. *N Engl J Med* 2014; 370: 699–708.
39. Chinot OL, Wick W, Mason W et al. Bevacizumab plus radiotherapy-temozolomide for newly diagnosed glioblastoma. *N Engl J Med* 2014; 370: 709–722.
40. van den Bent MJ, Brandes AA, Taphoorn MJ et al. Adjuvant procarbazine, lomustine, and vincristine chemotherapy in newly diagnosed anaplastic oligodendroglioma: long-term follow-up of EORTC Brain Tumor Group study 26951. *J Clin Oncol* 2013; 31: 344–350.
41. Cairncross G, Wang M, Shaw E et al. Phase III trial of chemoradiotherapy for anaplastic oligodendroglioma: long-term results of RTOG 9402. *J Clin Oncol* 2013; 31: 337–343.
42. Wick W, Hartmann C, Engel C et al. NOA-04 randomized phase III trial of sequential radiochemotherapy of anaplastic glioma with procarbazine, lomustine, and vincristine or temozolomide. *J Clin Oncol* 2009; 27: 5874–5880.
43. van den Bent MJ, Afra D, de Witte O et al. Long-term efficacy of early versus delayed radiotherapy for low-grade astrocytoma and oligodendroglioma in adults: the EORTC 22845 randomised trial. *Lancet* 2005; 366: 985–990.
44. Karim AB, Maat B, Hatlevoll R et al. A randomized trial on dose-response in radiation therapy of low-grade cerebral glioma: European Organization for Research and Treatment of Cancer (EORTC) study 22844. *Int J Radiat Oncol Biol Phys* 1996; 36: 549–556.
45. Shaw E, Arusell R, Scheithauer B et al. Prospective randomized trial of low- versus high-dose radiation therapy in adults with supratentorial low-grade glioma: initial report of a North Central Cancer Treatment Group/Radiation Therapy Oncology Group/Eastern Cooperative Oncology Group study. *J Clin Oncol* 2002; 20: 2267–2276.
46. Pignatti F, van den Bent M, Curran D et al. Prognostic factors for survival in adult patients with cerebral low-grade glioma. *J Clin Oncol* 2002; 20: 2076–2084.
47. Baumert BG, Mason WP, Ryan G et al. Temozolomide chemotherapy versus radiotherapy in molecularly characterized (1p loss) low-grade glioma: a randomized phase III intergroup study by the EORTC/NCIC-CTG/TROG/MRC-CTU (EORTC 22033–26033). *ASCO Meeting Abstracts*. *J Clin Oncol* 2013; 31: abstr 2007.
48. Shaw EG, Wang M, Coons SW et al. Randomized trial of radiation therapy plus procarbazine, lomustine, and vincristine chemotherapy for supratentorial adult low-grade glioma: initial results of RTOG 9802. *J Clin Oncol* 2012; 30: 3065–3070.
49. Yung WK, Prados MD, Yaya-Tur R et al. Multicenter phase II trial of temozolomide in patients with anaplastic astrocytoma or anaplastic oligoastrocytoma at first relapse. Temodal Brain Tumor Group. *J Clin Oncol* 1999; 17: 2762–2771.
50. Taal W, Dubbink HJ, Zonnenberg CB et al. First-line temozolomide chemotherapy in progressive low-grade astrocytomas after radiotherapy: molecular characteristics in relation to response. *Neuro Oncol* 2011; 13: 235–241.
51. Brada M, Stenning S, Gabe R et al. Temozolomide versus procarbazine, lomustine, and vincristine in recurrent high-grade glioma. *J Clin Oncol* 2010; 28: 4601–4608.
52. Wick W, Puduvalli VK, Chamberlain MC et al. Phase III study of enzastaurin compared with lomustine in the treatment of recurrent intracranial glioblastoma. *J Clin Oncol* 2010; 28: 1168–1174.
53. Batchelor TT, Mulholland P, Neyns B et al. Phase III randomized trial comparing the efficacy of cediranib as monotherapy, and in combination with lomustine, versus lomustine alone in patients with recurrent glioblastoma. *J Clin Oncol* 2013; 31: 3212–3218.
54. van den Bent MJ, Brandes AA, Rampling R et al. Randomized phase II trial of erlotinib versus temozolomide or carmustine in recurrent glioblastoma. EORTC Brain Tumor Group study 26034. *J Clin Oncol* 2009; 27: 1268–1274.
55. Dresemann G, Weller M, Rosenthal MA et al. Imatinib in combination with hydroxyurea versus hydroxyurea alone as oral therapy in patients with progressive pretreated glioblastoma resistant to standard dose temozolomide. *J Neurooncol* 2010; 96: 393–402.
56. Friedman HS, Prados MD, Wen PY et al. Bevacizumab alone and in combination with irinotecan in recurrent glioblastoma. *J Clin Oncol* 2009; 27: 4733–4740.
57. Kreisl TN, Kim L, Moore K et al. Phase II trial of single-agent bevacizumab followed by bevacizumab plus irinotecan at tumor progression in recurrent glioblastoma. *J Clin Oncol* 2009; 27: 740–745.

58. Stupp R, Wong ET, Kanner AA et al. NovoTTF-100A versus physician's choice chemotherapy in recurrent glioblastoma: a randomised phase III trial of a novel treatment modality. *Eur J Cancer* 2012; 48: 2192–2202.
59. Gorlia T, Stupp R, Brandes AA et al. New prognostic factors and calculators for outcome prediction in patients with recurrent glioblastoma: a pooled analysis of EORTC Brain Tumour Group phase I and II clinical trials. *Eur J Cancer* 2012; 48: 1176–1184.
60. Clarke JL, Ennis MM, Yung WK et al. Is surgery at progression a prognostic marker for improved 6-month progression-free survival or overall survival for patients with recurrent glioblastoma? *Neuro Oncol* 2011; 13: 1118–1124.
61. Brem H, Piantadosi S, Burger PC et al. Placebo-controlled trial of safety and efficacy of intraoperative controlled delivery by biodegradable polymers of chemotherapy for recurrent gliomas. The Polymer-brain Tumor Treatment Group. *Lancet* 1995; 345: 1008–1012.
62. Combs SE, Thilmann C, Edler L et al. Efficacy of fractionated stereotactic reirradiation in recurrent gliomas: long-term results in 172 patients treated in a single institution. *J Clin Oncol* 2005; 23: 8863–8869.
63. Fogh SE, Andrews DW, Glass J et al. Hypofractionated stereotactic radiation therapy: an effective therapy for recurrent high-grade gliomas. *J Clin Oncol* 2010; 28: 3048–3053.
64. Brandsma D, Stalpers L, Taal W et al. Clinical features, mechanisms, and management of pseudoprogression in malignant gliomas. *Lancet Oncol* 2008; 9: 453–461.
65. Brandes AA, Tosoni A, Spagnoli F et al. Disease progression or pseudoprogression after concomitant radiochemotherapy treatment: Pitfalls in neurooncology. *Neuro Oncol* 2008; 10: 361–367.
66. Brandes AA, Franceschi E, Tosoni A et al. MGMT promoter methylation status can predict the incidence and outcome of pseudoprogression after concomitant radiochemotherapy in newly diagnosed glioblastoma patients. *J Clin Oncol* 2008; 26: 2192–2197.
67. Wen PY, Macdonald DR, Reardon DA et al. Updated response assessment criteria for high-grade gliomas: response assessment in neuro-oncology working group. *J Clin Oncol* 2010; 28: 1963–1972.
68. Hottinger AF, Levivier M, Negretti L et al. PET imaging in glioma. The neuro-oncologist's expectations. *PET Clin* 2013; 8: 117–128.
69. Phillips HS, Kharbanda S, Chen R et al. Molecular subclasses of high-grade glioma predict prognosis, delineate a pattern of disease progression, and resemble stages in neurogenesis. *Cancer Cell* 2006; 9: 157–173.
70. Weller M, Pfister SM, Wick W et al. Molecular neuro-oncology in clinical practice: a new horizon. *Lancet Oncol* 2013; 14: e370–e379.
71. Brandes AA, Franceschi E, Tosoni A et al. Epidermal growth factor receptor inhibitors in neuro-oncology: hopes and disappointments. *Clin Cancer Res* 2008; 14: 957–960.
72. Dykewicz CA. Summary of the guidelines for preventing opportunistic infections among hematopoietic stem cell transplant recipients. *Clin Infect Dis* 2001; 33: 139–144.